

OVERVIEW

The cerebral cortex is divided into 49 macro-anatomically defined regions in each hemisphere that are of broad interest to the neuroimaging community. Region of interest (ROI) boundary definitions were derived from a number of cortical labeling methods currently in use. Protocols from the Laboratory of Neuroimaging at UCLA (LONI; Shattuck et al., 2008), the University of Iowa Mental Health Clinical Research Center (IOWA; Crespo-Facorro et al., 2000; Kim et al., 2000), the Center for Morphometric Analysis at Massachusetts General Hospital (MGH-CMA; Caviness et al., 1996), a collaboration between the Freesurfer group at MGH and Boston University School of Medicine (MGH-Desikan; Desikan et al., 2006), and UC San Diego (Carper & Courchesne, 2000; Carper & Courchesne, 2005; Carper et al., 2002) are specifically referenced in the protocol below. Methods developed at Boston University (Tourville & Guenther, 2003), Brigham and Women's Hospital (McCarley & Shenton, 2008), Stanford (Allan Reiss lab), the University of Maryland (Buchanan et al., 2004), and the University of Toyoma (Zhou et al., 2007) were also consulted. The development of the protocol was also guided by the Ono, Kubik, and Abernathy (1990), Duvernoy (1999), and Mai, Paxinos, and Voss (Mai et al., 2008) neuroanatomical atlases.

The protocol presented here is meant to i) maximize reliance upon robust anatomical landmarks, ii) minimize reliance upon arbitrary landmarks, and iii) base regional boundary definitions, to the degree possible, upon anatomical landmarks that lie immediately adjacent to that region.

Nomenclature. Neuroanatomical terms and abbreviations were drawn from the NeuroNames ontology developed by Bowden and Dubach (Bowden & Dubach, 2003; http://braininfo.rprc.washington.edu/track_page.aspx?ref=27). When a suitable term was not found in the NeuroNames database, a term and abbreviation consistent with the NeuroNames nomenclature was used. Region boundaries are listed in terms of relevant superior-inferior, anterior-posterior, and medial-lateral limits. These terms refer to directions in a standard reference frame formed by points at the decussation of the anterior and posterior commissures. The descriptors ventral, dorsal, rostral, and caudal are used to describe intrinsic relative spatial relationships.

Boundary conventions. Sulci represent the most common type of regional boundary. When a sulcus is listed as a boundary, the boundary is formed by the fundus of that sulcus. Boundaries for several ROIs are given by the margins, or “corners”, of prominent sulcal banks. Examples are the superior margin of the interhemispheric sulcus, the lateral margin of the lateral sulcus, and the medial margin of the calcarine sulcus. These boundaries are formed by a line orthogonal to the cortical sheet at the sulcal margin, i.e., a line that passes from the cortical surface margin through the cortex to the underlying white matter margin. Figure 1 shows how sulcal and marginal boundaries are formed. Dividing planes based on anatomical landmarks are also used as boundaries. Such planes often lie parallel to a principle axis in a common reference space (e.g., aligned to the axis formed by a line through the anterior and posterior commissures), but may be oblique. The plane dividing the parietal and occipital lobes on the lateral surface is an example of an oblique dividing plane.

Figure 1. Examples of common regional boundary types are demonstrated on a cortical ribbon shown in the coronal plane. Black and red lines through the cortex mark boundaries between adjacent cortical regions of interest. Black lines are drawn through the fundi of delimiting sulci. The red lines are drawn approximately orthogonal to the cortical surface through sulcal bank margins. The superior margin of the interhemispheric sulcus (line 1), the lateral margin of the dorsal bank of the lateral sulcus (line 2) and the lateral margin of the ventral bank of the lateral sulcus (line 3) are identified.

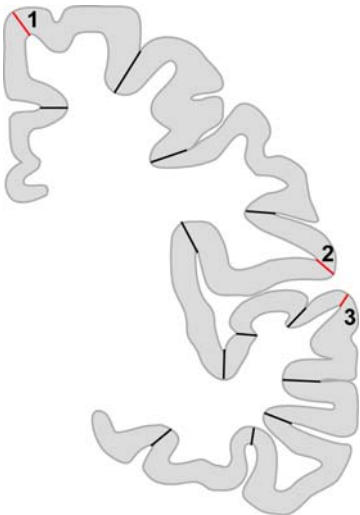


Table 1. Sulci included in the protocol and their abbreviations

aals	anterior ascending ramus of the lateral sulcus
ahls	anterior horizontal ramus of the lateral sulcus
aocs	anterior occipital sulcus
cas	callosal sulcus
ccs	calcarine sulcus
cgs	cingulate sulcus
cis	central insular sulcus
cos	collateral sulcus
crs	circular insular sulcus
cs	central sulcus
fms*	frontomarginal sulcus
ftts*	first transverse temporal sulcus
hs*	Heschl's sulcus
ifrs	inferior frontal sulcus
ihs*	interhemispheric sulcus
ltts*	intermediate transverse temporal sulcus
iros	inferior rostral sulcus
itps	intraparietal sulcus
its	inferior temporal sulcus
lhos*	lateral H-shaped orbital sulcus
locs	lateral occipital sulcus
los	lateral orbital sulcus
ls	lateral sulcus
mhos*	medial H-shaped orbital sulcus
olfs	olfactory sulcus
ots	occipitotemporal sulcus
pals	posterior ascending ramus of the lateral sulcus
phls	posterior horizontal ramus of the lateral sulcus
pis*	primary intermediate sulcus
pocs	postcentral sulcus
pos	parietooccipital sulcus
prcs*	precentral sulcus
sbps	subparietal sulcus
sfrs	superior frontal sulcus
sros	superior rostral sulcus
sts	superior temporal sulcus
thos	transverse H-shaped orbital sulcus

* Anatomical label and abbreviation not included in the NeuroNames database

Table 2. Regions of interest included in the protocol and their abbreviations.

ACgG	anterior cingulate gyrus
Alns*	anterior insula
AnG	angular gyrus
AOrG	anterior orbital gyrus
Calc*	calcarine cortex
CgG	cingulate gyrus
CO	central operculum
Cun	cuneus
Ent	entorhinal area
FO	frontal operculum
FRP	frontal pole
FuG	fusiform gyrus
GRe	gyrus rectus
IFG	inferior frontal gyrus
IOG	inferior occipital gyrus
ITG	inferior temporal gyrus
LiG	lingual gyrus
LOrG	lateral orbital gyrus
MCgG*	middle cingulate gyrus
MFC*	medial frontal cortex
MFG	middle frontal gyrus
MOG*	middle occipital gyrus
MOrG	medial orbital gyrus
MPoG	postcentral gyrus, medial segment
MPrG	precentral gyrus, medial segment
MSFG	superior frontal gyrus, medial segment
MTG	middle temporal gyrus
OCP	occipital pole
OFC*	orbitofrontal cortex
OFuG*	occipital fusiform gyrus
OplFG	opercular part of the inferior frontal gyrus
OrIFG	orbital part of the inferior frontal gyrus
PCgG	posterior cingulate gyrus
PCu	precuneus
PHG	parahippocampal gyrus
Pins*	posterior insula
PO	parietal operculum
PoG	postcentral gyrus
POrG	posterior orbital gyrus
PP*	planum polare
PrG	precentral gyrus
PT*	planum temporale
SCA	subcallosal area
SFG	superior frontal gyrus
SMC*	supplementary motor cortex
SMG	supramarginal gyrus
SOG	superior occipital gyrus
SPL	superior parietal lobule
STG	superior temporal gyrus
TMP	temporal pole
TriFG	triangular part of the inferior frontal gyrus
TTG	transverse temporal gyrus

* Region label and abbreviation not included in the NeuroNames database

Table 3. Dividing planes included in the protocol and their abbreviations.

The following dividing planes are used in the protocol. Planes are coronal unless specified otherwise:

calc-ant	anterior limit of the calcarine sulcus
calc-post	posterior limit of the calcarine sulcus
cos-ant	anterior limit of the collateral sulcus
cs-med	dorsomedial limit of the central sulcus;
genu-post	marked by the posterior limit of the genu of the corpus callosum
ifs-ant	anterior limit of the inferior temporal sulcus
hip-ant	anterior limit of the hippocampus
mhos-ant	anterior limit of the medial H-shaped orbital sulcus
occ-ant	oblique medial-lateral plane given by a line drawn through points at (i) ventrolateral limit of the anterior occipital sulcus, (ii) jct of the lateral occipital sulcus and the anterior occipital sulcus, and (iii) the dorsomedial limit of the parietooccipital sulcus
ots-ant	anterior limit of the occipitotemporal sulcus
prcs-med	dorsomedial limit of the precentral sulcus
prcs-lat	ventrolateral limit of the precentral sulcus
pocs-lat	ventrolateral limit of the postcentral sulcus
pos-ant	anterior limit of the ventral bank of the parietooccipital sulcus
tf-jct	junction of the temporal and frontal lobes
splen-ant	anterior limit of the splenium of the corpus callosum

SCHEMATICS OF THE LABELING PROTOCOL

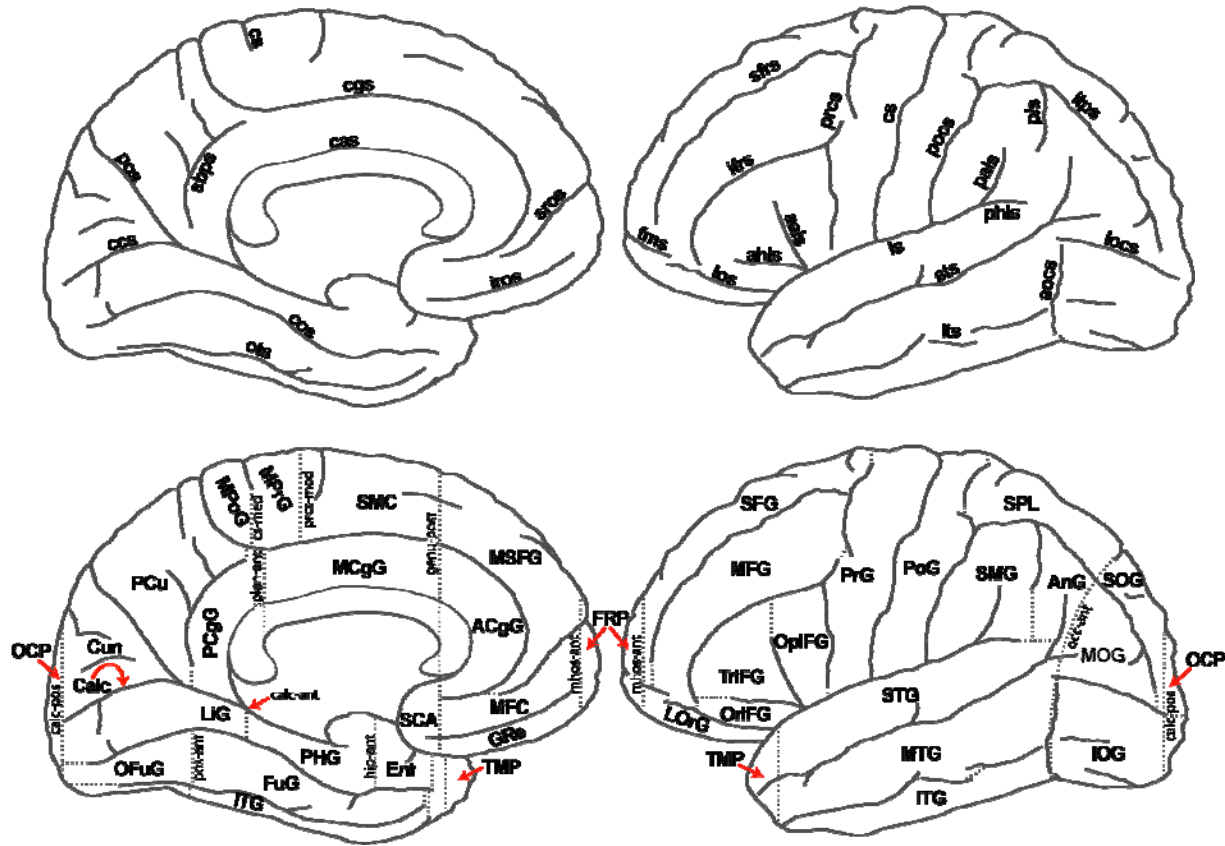


Figure 2. Region-delimiting sulci (top) and proposed regions of interest (bottom) of the medial (left) and lateral (right) cortical surfaces are schematized (see lists above for abbreviation definitions). All regions, including optional regions are shown with the exception of entorhinal cortex. Boundaries not formed by sulci are indicated by dotted lines. Dividing planes are labeled (all lower case; dotted lines that are not labeled represent simple extensions of sulci). The curved arrow from the Calcarine Cortex ROI (Calc) to the calcarine sulcus indicates that the ROI lies within the sulcus.

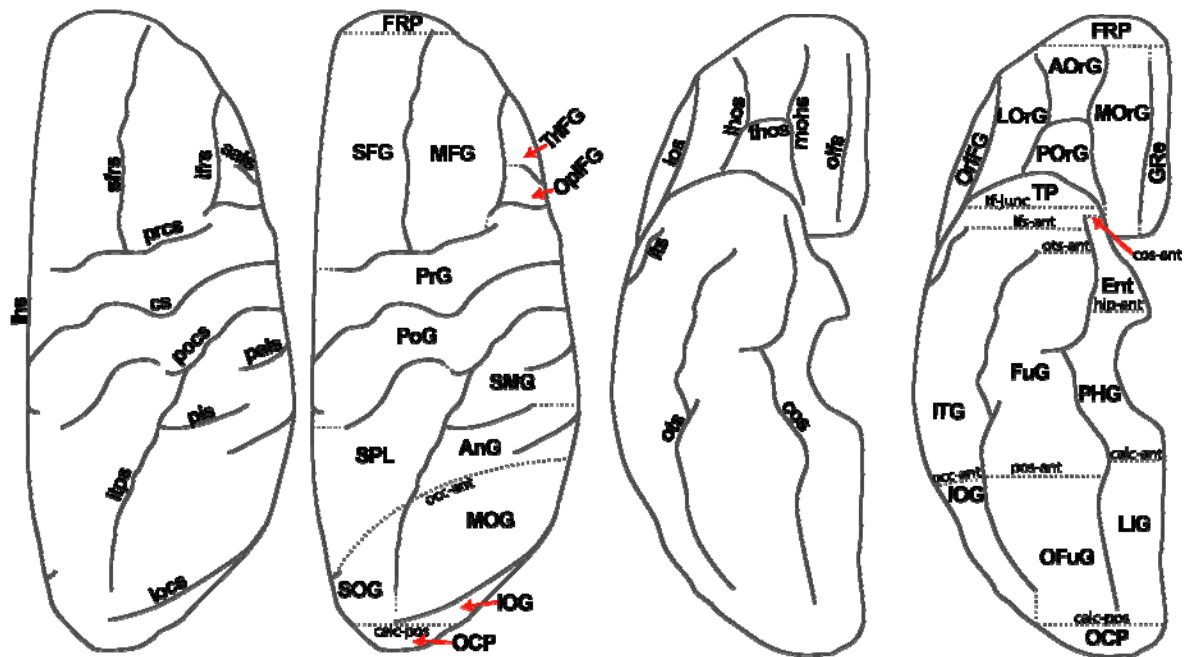


Figure 3. Sulci and ROIs are shown on the dorsal (left group) and ventral (right group) surfaces. Boundaries not formed by sulci are indicated by dotted lines. Dividing planes are labeled (all lower case; dotted lines that are not labeled represent simple extensions of sulci).

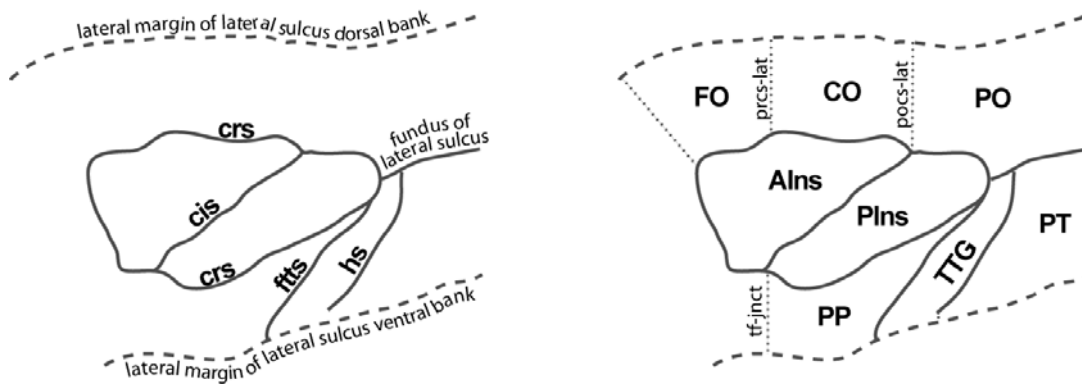


Figure 4. Sulci (left) and ROIs (right) within the banks of the lateral sulcus are shown. The region is schematized in pseudo-flattened form: the insula, in the center, is flanked by the dorsal and ventral banks of the lateral sulcus. Boundaries not formed by sulci are indicated by dotted lines. Dividing planes are labeled (all lower case; dotted lines that are not labeled represent the termination of lateral sulcus).

CORTICAL LABELING PROTOCOL

1. Frontal Lobe(FL)

1.1. Lateral Surface

1.1.1. Frontal Pole (FRP)

Anterior: anterior margin of the frontal gyrus

Posterior: anterior limit of the medial orbitofrontal sulcus

1.1.2. Superior Frontal Gyrus (SFG)

Anterior: frontomarginal sulcus

Posterior: precentral sulcus / plane prcs-med

Medial: superior margin of interhemispheric fissure

Inferior: *anteriorly*: lateral orbital sulcus; *posteriorly*: middle frontal sulcus

1.1.3. Middle Frontal Gyrus (MFG)

Posterior: precentral sulcus

Superior: superior frontal sulcus

Inferior: *anteriorly*: lateral orbital sulcus; *posteriorly*: inferior frontal sulcus

1.1.4. Inferior Frontal Gyrus (IFG)

Posterior: precentral sulcus

Superior/anterior: *anteriorly*: lateral orbital sulcus; *posteriorly*: inferior frontal sulcus

Inferior: *anteriorly*: lateral orbital sulcus; *posteriorly*: lateral orbital sulcus / posterior projection from the posterior limit of the lateral orbital sulcus to the lateral sulcus

1.1.5. Opercular part of the Inferior Frontal Gyrus (OpIFG; optional: if subdivide IFG)

Anterior: anterior ascending ramus of the lateral sulcus (aals) / dorsal projection from the superior limit of the aals to the inferior frontal sulcus

Posterior: precentral sulcus

Superior: inferior frontal sulcus

Inferior: (i) if aals branches from the lateral sulcus: lateral sulcus, (ii) if aals branches from the anterior horizontal limb of the lateral sulcus (ahls): ahls;

1.1.6. Orbital part of the Inferior Frontal Gyrus (OrIFG; optional: if subdivide IFG)

Anterior: inferior frontal sulcus

Posterior: lateral sulcus / anterior ascending ramus of the lateral sulcus (aals)

Superior: anterior horizontal limb of the lateral sulcus (ahls) / anterior projection of the ahls to the inferior frontal sulcus

Inferior: *anteriorly*: lateral orbital sulcus; *posteriorly*: posterior projection from the posterior limit of the lateral orbital sulcus to the lateral sulcus

1.1.7. Triangular part of the Inferior Frontal Gyrus (TrIFG; optional: if subdivide IFG)

Anterior/Superior: inferior frontal sulcus

Posterior: anterior ascending ramus of the lateral sulcus (aals) / dorsal projection from the superior limit of the aals to the inferior frontal sulcus

Inferior: anterior horizontal limb of the lateral sulcus (ahls)/ anterior projection of the ahls to the inferior frontal sulcus

1.1.8. Precentral Gyrus (PrG)

Anterior: precentral sulcus

Posterior: central sulcus
Superior: superior margin of the interhemispheric fissure
Inferior: lateral margin of the dorsal bank of the lateral fissure

1.2. Medial Surface

1.2.1. Superior Frontal Gyrus (MSFG; medial segment)

Anterior: anterior limit of medial H-shaped orbital sulcus (mhos-ant)
Posterior: medial limit of the precentral sulcus
Superior: interhemispheric fissure, hemispheric margin
Inferior: *anteriorly*: superior rostral sulcus; *posteriorly*: cingulate sulcus; if the superior rostral sulcus does not continue to the posterior limit of subcallosal cortex and does not intersect with the cingulate sulcus, the inferior boundary will be completed by a posterior projection from the posterior limit of the superior rostral sulcus to the cingulate sulcus

1.2.2. Supplementary Motor Cortex (SMC; optional)

Anterior: posterior limit of the genu of the corpus callosum (plane genu-post)
Posterior: dorsomedial limit of the precentral sulcus (plane prcs-med)
Superior: superior margin of the interhemispheric fissure
Inferior: cingulate sulcus

1.2.3. Medial Frontal Cortex (MFC; optional)

Anterior: anterior limit of medial H-shaped orbital sulcus (mhos-ant)
Posterior: posterior limit of the genu of the corpus callosum (genu-post)
Superior: *anteriorly*: superior rostral sulcus; *posteriorly*: cingulate sulcus; if the superior rostral sulcus does not continue to the posterior limit of subcallosal cortex and does not intersect with the cingulate sulcus, the superior boundary is completed by a posterior projection from the posterior limit of the superior rostral sulcus

Inferior: inferior rostral sulcus

1.2.4. Gyrus Rectus (GRe; optional: is subset of medial frontal cortex)

Anterior: anterior hemispheric margin
Posterior: posterior limit of the genu of the corpus callosum (genu-post)
Superior: inferior rostral sulcus
Inferior: olfactory sulcus

1.2.5. Subcallosal Area (SCA; optional)

Anterior: posterior limit of the genu of the corpus callosum (genu-post)
Posterior: posterior limit of medial frontal cortex
Superior: cingulate sulcus
Inferior: olfactory sulcus (alternative: inferior rostral sulcus)

1.2.6. Precentral Gyrus (MPrG; medial segment)

Anterior: plane prcs-med
Posterior: plane cs-med
Superior: superior margin of the interhemispheric sulcus
Inferior: cingulate sulcus

1.3. Inferior Surface

1.3.1. Anterior Orbital Gyrus (AOrG)

Anterior: anterior limit of the medial H-shaped orbital sulcus (mhos)
Posterior: transverse H-shaped orbital sulcus

Medial: medial H-shaped orbital sulcus

Lateral: lateral H-shaped orbital sulcus

1.3.2. Medial Orbital Gyrus (MOrG)

Anterior: anterior limit of the medial H-shaped orbital sulcus (mhos)

Posterior: posterior limit of the orbital frontal gyrus

Medial: medial H-shaped orbital sulcus

Lateral: olfactory sulcus

1.3.3. Lateral Orbital Gyrus (LOrG)

Anterior: anterior limit of the medial H-shaped orbital sulcus (mhos)

Posterior: posterior limit of orbital frontal cortex

Medial: lateral H-shaped orbital sulcus

Lateral: *anteriorly*: lateral orbital sulcus; *posteriorly*: posterior projection from the posterior limit of the lateral orbital sulcus to the lateral sulcus

1.3.4. Posterior Orbital Gyrus (POrG)

Anterior: transverse H-shaped orbital sulcus

Posterior: posterior limit of orbital frontal cortex

Medial: medial H-shaped orbital sulcus

Lateral: lateral H-shaped orbital sulcus

1.4. Opercular Region

1.4.1. Frontal Operculum (FO)

Anterior: anterior limit of the insula

Posterior: plane prcs-lat

Medial: circular sulcus of the insula

Lateral: lateral margin of the dorsal bank of the lateral sulcus

1.4.2. Central Operculum (CO)

Anterior: plane prcs-lat

Posterior: plane pocs-lat

Medial: circular sulcus of the insula

Lateral: lateral margin of the dorsal bank of the lateral sulcus

1.4.3. Parietal Operculum (PO)

Anterior: plane pocs-lat

Posterior: posterior limit of the ventral bank of the ascending ramus of the posterior lateral sulcus

Medial: circular sulcus of the insula

Lateral: lateral margin of the dorsal bank of the posterior ascending ramus of the lateral sulcus

1.5. Insular Region

1.5.1. Anterior Insula (AIns)

Anterior/Superior/Inferior: circular sulcus of the insula

Posterior: central sulcus of the insula

1.5.2. Posterior Insula (PIns)

Anterior: central sulcus of the insula

Posterior/Superior/Inferior: circular sulcus of the insula

2. Temporal Lobe (TL)

2.1. Lateral Surface

2.1.1. Temporal Pole (TMP)

Anterior: anterior limit of the temporal lobe

Posterior: junction of the temporal and frontal lobes (tf-junct)

2.1.2. Superior Temporal Gyrus (STG)

Anterior: junction of the temporal and frontal lobes (tf-junct)

Posterior (see LONI): (i) if a posterior horizontal ramus of the lateral sulcus (phls; note that this ramus of the lateral sulcus is termed the descending ramus by some authors) is present: junction of the posterior descending ramus of the lateral sulcus (phls) and the superior temporal sulcus / posterior projection from the posterior limit of the phls to the superior temporal sulcus; (ii) if a posterior horizontal ramus of the lateral sulcus is not present: junction of the lateral sulcus and the superior temporal sulcus / posterior projection from the posterior limit of the lateral sulcus to the superior temporal sulcus that parallels the trajectory of the lateral sulcus

Superior: lateral margin of the ventral bank of the lateral sulcus / posterior horizontal ramus of the lateral sulcus

Inferior: superior temporal sulcus

2.1.3. Middle Temporal Gyrus (MTG)

Anterior: junction of the temporal and frontal lobes (tf-junct)

Posterior: the anterior limit of the occipital lobe (occ-ant)

Superior: superior temporal sulcus; anterior projection of the inferior temporal sulcus to the anterior limit of temporal lobe

Inferior: inferior temporal sulcus

2.1.4. Inferior Temporal Gyrus (ITG)

Anterior: junction of the temporal and frontal lobes (tf-junct)

Posterior: plane occ-ant

Superior: inferior temporal sulcus

Inferior: occipitotemporal sulcus

2.2. Supratemporal Surface (optional)

2.2.1. Planum Polare (PP)

Anterior: junction of the temporal and frontal lobes (tf-junct)

Posterior: junction of the first transverse sulcus and the circular sulcus of the insula

Medial: circular sulcus of the insula

Lateral: lateral margin of the ventral bank of the posterior lateral sulcus

2.2.2. Transverse Temporal Gyrus (TTG)

Anterior: first transverse sulcus, anterior limit

Posterior: posterior limit of Heschl's sulcus

Medial: *anteriorly*: first transverse temporal sulcus; *intermediately*: circular sulcus of the insula; *posteriorly*: lateral sulcus

Lateral: *anteriorly*: lateral margin of the ventral bank of the posterior lateral sulcus; *posteriorly*: Heschl's sulcus (most anterior sulcus coursing postero-medially to antero-laterally along the ventral bank of the lateral sulcus *that arises from the retroinsular region of the lateral sulcus*); if an intermediate transverse temporal sulcus is present (sulcus lying between the first transverse sulcus and Heschl's sulcus that *does not extend posteriorly to the circular sulcus or the retroinsular region of the lateral sulcus*, the lateral border is

formed by the intermediate transverse temporal sulcus for regions anterior to the anterior limit of the Heschl's sulcus (see Kim et al.,2000, for greater detail)

2.2.3. Planum Temporal (PT)

Anterior: anterior limit of Heschl's sulcus

Posterior: posterior limit of the ventral bank of the ascending ramus of the posterior lateral sulcus

Medial: *anteriorly*: Heschl's sulcus; if an intermediate transverse temporal sulcus is present, the medial border is formed by this sulcus for regions anterior to the anterior limit of Heschl's sulcus (see Kim et al.,2000); *posteriorly*: lateral sulcus / posterior ascending ramus of the lateral sulcus

Lateral: lateral margin of the ventral bank of the lateral sulcus / posterior ascending ramus of the lateral sulcus

2.3. Inferior Surface

2.3.1. Fusiform Gyrus (FuG)

Anterior: anterior limit of the occipitotemporal sulcus

Posterior: plane pos-ant (if divide into Fusiform and Occipital Fusiform segments)
[alternative: temporooccipital notch]

Medial: collateral sulcus

Lateral: occipitotemporal sulcus

3. Parietal lobe (PL)

3.1. Lateral Surface

3.1.1. Postcentral Gyrus (PoG)

Anterior: central sulcus

Posterior: postcentral sulcus

Superior: superior margin of the interhemispheric fissure

Inferior: lateral margin of the dorsal bank of the posterior lateral fissure

3.1.2. Supramarginal Gyrus (SMG)

Anterior: postcentral sulcus

Posterior: primary intermediate sulcus (pis) / inferior projection from the inferior limit of pis to the superior temporal sulcus

Superior: intraparietal sulcus

Inferior: anterior to the posterior limit of the posterior lateral sulcus (pls): lateral margin of the dorsal bank of the pls; posterior to pls: superior temporal sulcus

3.1.3. Superior Parietal Lobule (SPL)

Anterior: postcentral sulcus

Posterior: plane occ-ant

Superior: superior margin of the interhemispheric sulcus

Inferior: intraparietal sulcus

3.1.4. Angular Gyrus (AnG)

Anterior: primary intermediate sulcus (pis) / inferior projection from the inferior limit of pis to the superior temporal sulcus

Posterior: plane occ-ant

Superior: intraparietal sulcus

Inferior: superior temporal sulcus, anterior occipital sulcus, or lateral occipital sulcus (see Crespo-Facarro for convention)

3.2. Medial Surface

3.2.1. Postcentral Gyrus (MPoG, medial segment)

Anterior: plane cs-med ;

Posterior: marginal ramus of the cingulate sulcus

Superior: interhemispheric margin

Inferior: cingulate sulcus

3.2.2. Precuneus (PCu)

Anterior: *superiorly*: marginal ramus of the cingulate sulcus (superior region);
inferiorly: subparietal sulcus; if the subparietal sulcus does not intersect the calcarine sulcus, an inferior projection from the inferior limit of the subparietal sulcus to the calcarine sulcus serves as the anterior boundary

Posterior: parietooccipital sulcus

Superior: superior margin of the interhemispheric sulcus

Inferior: *superiorly*: subparietal sulcus; if the subparietal sulcus does not intersect the cingulate sulcus, a projection from the anterior limit of the subparietal sulcus to the nearest point of the cingulate sulcus will serve as the inferior boundary; *inferiorly*: calcarine sulcus

4. Occipital Lobe (OL)

4.1. Lateral Surface

4.1.1. Superior Occipital Gyrus (SOG)

Anterior: plane occ-ant

Posterior: posterior margin of the interhemispheric sulcus

Superior: superior margin of the interhemispheric sulcus

Inferior: lateral occipital sulcus (locs); if the locs does not intersect the hemispheric margin, a posterior projection from the posterior limit of the locs to the posterior hemispheric margin serves as the superior boundary

4.1.2. Inferior Occipital Gyrus (IOG)

Anterior: plane occ-ant

Posterior: posterior margin of the interhemispheric sulcus

Superior: lateral occipital sulcus (locs); if the locs does not intersect the hemispheric margin, a posterior projection from the posterior limit of the locs to the posterior hemispheric margin serves as the superior boundary

Inferior: occipitotemporal sulcus (ots); if the ots does not extend to the posterior cortical limit, a posterior projection from the posterior limit of ots serves as the lateral boundary

4.1.3. Middle Occipital Gyrus (MOG; optional)

Anterior: plane occ-ant

Posterior: (i) if the junction lateral occipital sulcus (locs) and the intraparietal sulcus (ipts) meet the posterior hemispheric margin: the posterior hemispheric margin; (ii) if the locs, and itps meet: the junction of the locs and itps; (iii) if the locs and itps do not meet, the boundaries in the posterior aspect of the region will be served by a posterior projection from the posterior limit of the locs and an inferior projection of the itps

Superior: intraparietal sulcus (ipts); if the itps does not meet the posterior hemispheric margin, an inferior projection from the inferior limit of the itps will serve as the superior boundary

Inferior: lateral occipitotemporal sulcus (locs); if the locs does not meet the posterior hemispheric margin, a posterior projection from the posterior limit of the itps will serve as the inferior boundary

4.1.4. Occipital Pole

Anterior: posterior limit of the calcarine sulcus (calc-pos)

Posterior: posterior limit of the occipital lobe

4.2. Inferior Surface

4.2.1. Occipital Fusiform Gyrus (OFuG, optional)

Anterior: plane pos-ant [alternative: temporooccipital notch]

Posterior: posterior hemispheric margin

Medial: collateral sulcus

Lateral: occipitotemporal sulcus (ots); if the ots does not intersect the posterior hemispheric margin, a posterior projection from the posterior limit of ots serves as the lateral boundary

4.3. Medial Surface

4.3.1. Cuneus (Cun)

Anterior: parietooccipital sulcus

Posterior: posterior hemispheric margin

Superior: superior margin of the interhemispheric sulcus

Inferior: lateral margin of the dorsal bank of the calcarine sulcus

4.3.2. Calcarine Cortex (Calc, optional)

Anterior: parietooccipital sulcus

Posterior: posterior limit of the calcarine sulcus

Superior: lateral margin of the dorsal bank of the calcarine sulcus

Inferior: lateral margin of the ventral bank of the calcarine sulcus

4.3.3. Lingual Gyrus (LiG)

Anterior: anterior limit of the calcarine sulcus [a suitable alternative would be the posterior limit of the hippocampus]

Posterior: posterior hemispheric margin

Medial: calcarine sulcus

Lateral: collateral sulcus / posterior projection of the lateral sulcus to the hemispheric margin (see Crespo-Facarro for conventions)

5. Limbic Cortex

5.1. Cingulate Cortex

5.1.1. Anterior cingulate gyrus (ACgG)

Anterior: anterior limit of the cingulate sulcus (if a “double parallel” cingulate sulcus is present (paracingulate sulcus), the anterior-most sulcus will serve as the cingulate sulcus)

Posterior: *supra-callosal area*: posterior limit of the genu of the corpus callosum (genu-post); *sub-callosal area*: posterior limit of medial frontal cortex

Superior: *supra-callosal area*: cingulate sulcus (if a “double parallel” cingulate sulcus is present (paracingulate sulcus), the anterior-most sulcus will serve as the cingulate sulcus); *sub-callosal area*: callosal sulcus

Inferior: *supra-callosal area*: callosal sulcus; *sub-callosal area*: superior rostral sulcus / posterior projection from the posterior limit of the superior rostral sulcus

5.1.2. Middle cingulate gyrus (MCgG)

Anterior: posterior limit of the genu of the corpus callosum (genu-post)

Posterior: anterior limit of the splenium of the corpus callosum (splen-ant)

Superior: cingulate sulcus

Inferior: callosal sulcus

5.1.3. Posterior cingulate gyrus (PCgG)

Anterior: anterior limit of the splenium of the corpus callosum (splen-ant)

Posterior: subparietal sulcus / inferior projection from the inferior limit of the subparietal sulcus

Superior: *supra-callosal area*: cingulate sulcus; *sub-callosal area*: callosal sulcus

Inferior: *supra-callosal area*: callosal sulcus; *sub-callosal area*: calcarine sulcus

5.2. Medial Temporal Cortex

5.2.1. Parahippocampal Gyrus (PHG)

Anterior: anterior limit of the hippocampus (tif-ant)

Posterior: anterior limit of the calcarine sulcus [a suitable alternative would be the posterior limit of the hippocampus]

Medial: CMA/Neuromorphometric definition for the hippocampus: a line from the dorsomedial limit of the sub-hippocampal white matter to the dorsomedial limit of the temporal cortex. This boundary is meant to include the subiculum, presubiculum, and parasubiculum within the hippocampus ROI during the segmentation procedure. [The segmentation is carefully done by an experienced rater so I think we should simply rely on this for the medial parahippocampal gyrus boundary. A good alternative that relies more completely on sulci is the Crespo-Facarro method].

Lateral: collateral sulcus

5.2.2. Entorhinal Area (Ent)

Anterior: the junction of the temporal and frontal lobes (tf-junct); if the collateral sulcus does not extend anteriorly to the tf-junc, then the anterior limit of the collateral sulcus (plane cos-ant)

Posterior: anterior limit of the hippocampus (hip-ant)

Medial: *anteriorly*: dorsal limit of the medial temporal lobe; *posteriorly*: CMA/Neuromorphometric definition for the amygdala: a line from the dorsomedial limit of the sub-amygdalar white matter to the dorsomedial margin of the temporal cortex.

Lateral: collateral sulcus/line projecting anteriorly from the anterior limit of the collateral sulcus

NOTES ON VARIABLE REGIONS.

In the section that follows, regions that are defined variably across protocols are discussed. Also addressed are regions that I have described in the protocol but consider optional. I am looking for feedback regarding whether these regions should be included. The format of the first several entries is a discussion of regional variability and a recommendation from Dr. Carper (Arial font) followed by a response regarding how this is addressed in the protocol from me (Times New Roman font). This format is meant highlight these issue and how they were (or were not) resolved in hopes that it will foster further comment from Dr. Salamon and other evaluators of the protocol.

Frontal / Parietal boundary—medial aspect. On the lateral aspect, this boundary is straightforward and MRI parcellation protocols consistently define the boundary as the Central Sulcus (CS). Protocols vary with regard to the medial aspect and include: **A**) coronal plane determined by any of – superior Central Sulcus (Iowa, MGH), superior Precentral Sulcus (MGH), posterior corpus callosum (Stanford, Brigham&Women's); **B**) projection of the medial limit of the Central Sulcus to the interhemispheric fissure (e.g. in the axial plane this is done by drawing a straight line between the CS and the interhemispheric fissure; LONI, Carper & Moses). → Recommendation: In the case where the CS is used to define a coronal plane or to produce a projection, the results are probably of comparable relevance and reliability, although both of these approaches have limitations. However, once the required CS is drawn, it would be trivial to offer both these approaches as alternatives.

This division is based on the coronal plane given by the medial limit of the central sulcus.

Frontal pole. Anterior limits of frontal gyri. Some groups include a frontal pole region, variously defined (e.g. MGH, Brigham&Women's, Desikan et al.). Several others use the fronto-marginal sulcus and lateral orbital sulcus to separate from orbital surface (LONI, Stanford, Iowa, Carper&Moses, Buchanan et al.). → Recommendation: Add the fronto-marginal and lateral orbital sulci as optional boundaries given that they are used so frequently. I find it's fairly straightforward to identify the FMS in the coronal plane.

I have omitted “pole” regions from the protocol. The fronto-marginal and lateral orbital sulci are included in the protocol to extend the superior frontal, medial frontal, and orbitofrontal regions to the anterior limit of the hemisphere.

Subregions of the orbital-frontal cortex. (Several useful figures are found at the end of the Brigham-Womens' manual). Among protocols that subparcel the orbital frontal cortex, different ROIs are used (e.g. Stanford, Brigham-Women's, MGH). However, all seem to rely on one or other combination of the: lateral orbital sulcus, fronto-marginal sulcus, lateral branch of H-shaped sulci, medial branch of H-shaped sulci, and olfactory sulcus. → Recommendation: Consider identifying all of these separately which would allow whatever combination is desired. However, these sulci are fairly variable in their morphology which may limit options.

Given the variability of the orbitofrontal sulci, I have defined a single orbitofrontal ROI that is bounded by the olfactory sulcus and the frontomarginal sulcus. This could be further subdivided if there is a sufficient call from the community to do so.

Medial subregions of frontal lobe. Only Iowa and MGH had subregions other than cingulate. Most others include medial aspect with superior frontal gyrus. → Recommendation: MGH protocol should be sufficient.

I decided against including a paracingulate ROI given the variability of the paracingulate sulcus. However, I did suggest an optional supplementary motor area region based on the IOWA and MGH-CMA definitions.

Treatment of the cingulate gyrus. The primary boundary is always the cingulate sulcus, although some protocols do not separate the cingulate from the frontal and parietal lobes. The posterior boundary of the cingulate varies, with some using the same definition that they use for the frontal/parietal boundary (Iowa, Brigham&Women's) and others using a unique definition (MGH). → Recommendation: Use same approach(es) as for the Frontal/Parietal boundary (above).

I suggested two options for subdividing the cingulate gyrus. One is based on callosal landmarks, another on the frontal/parietal boundary. These are described in detail in the protocol.

Parietal / Temporal boundary—lateral aspect. This boundary varies between protocols including: A) superior temporal sulcus and/or horizontal ramus of Sylvian (LONI, Iowa, MGH, Desikan), B) geometrically and anatomically defined cutting planes (Brigham&Women's, Carper&Moses). → Recommendation: Methods under 'A' appear to be relevant and reliable, are accepted by multiple research groups, and map fairly well to Brodmann's areas. Protocols vary in their details and should be compared directly.

I proposed a division based on the horizontal ramus of the Sylvian (lateral sulcus).

Subregions of the parietal lobe. The target regions on the lateral surface are typically the postcentral gyrus, supramarginal gyrus, angular gyrus, and superior parietal lobule (Stanford, Iowa, Brigham&Women's, Zhou et al., MGH, Desikan et al.). The boundaries of the postcentral gyrus are consistently defined, as is the inferior boundary of the superior parietal lobule. Protocols for the superior boundary of the superior parietal lobule vary with some stopping at the interhemispheric fissure, and others including the entire medial parietal lobe (precuneus). Boundary between supramarginal and angular varies. → Recommendation: Protocols vary in their details and should be compared directly. Use a sulci-defined protocol that is most similar to Brodmann's areas since this will likely be most similar to multiple research groups (Stanford perhaps?).

The primary intermediate sulcus (Jensen's) is proposed for the division between the supramarginal and angular gyri. This is consistent with most methods and is likely the best option. However, identifying this fissure is often difficult. An upside of this project is that by analyzing hundreds of brain, we may be able to improve the reliability of this and other difficult boundaries.

I proposed using the interhemispheric margin to divide the superior parietal lobule on the lateral surface from the precuneus on the medial surface. This landmark is easily identified, providing a robust way to subdivide a large cortical area. However, it ignores cytoarchitectonic (Brodmann) divisions which are better served by a region that continues from the intraparietal sulcus laterally

to (or near to) the subparietal sulcus medially. Is there a suitable landmark for dividing the precuneus into subregions that approximates to cytoarchitectonic subregions (ie., separate BA area 7 from 31)?

Occipital lobe boundary—lateral and inferior aspects. The classic definition of the occipital lobe identifies the parieto-occipital sulcus (POS) as the anterior boundary on the medial aspect, but the boundaries on the lateral and inferior aspects are arbitrary with little dependence on sulci. Because of this, MRI parcellation protocols consistently define the medial aspect of the occipital boundary as the POS but boundaries for the lateral and inferior aspects vary including: **A**) a coronal slice defined by a single point (e.g. MGH); **B**) the projection of the POS from the medial to the lateral surface (eg. Iowa); **C**) a boundary along the lateral surface defined by multiple points and sulci (e.g. Brigham & Women's, Carper & Moses, LONI, Desikan). The latter require actions in 3-dimensional space such as the creation of oblique planes based on anatomical landmarks and in some cases specialized algorithms. → Recommendation: A boundary based on landmarks on the lateral surface ('C') will be the most reliable and anatomically relevant and should therefore be used. However, both 'A' and 'B' are easily derived once the POS is traced, and can be replicated by any research group using any software. It would therefore be trivial and valuable to include them as alternate methods.

I propose using the Carper & Moses method because it best meets our goal of relying upon nearby relevant landmarks. The method relies on defining an oblique plane (or arc) through three points identifiable on the lateral surface. Two of the three landmarks, however, rely on the anterior occipital sulcus which may prove difficult to reliably identify. A common alternative is to project the parietooccipital sulcus onto the lateral surface. If we hear that the majority of groups prefer such a method, it would be easily adapted.

Subregions of the occipital lobe. Those that separate these are primarily Iowa and MGH. Both use similar protocols with the exception that MGH separates a polar region, while Iowa extends boundaries to posterior limit of cerebrum. → Recommendation: Use MGH approach which appears to be more complete.

I proposed a hybrid set of regions that extend to the posterior hemispheric limit. I eliminated two of the medial regions in the MGH-CMA protocol because they are based on a highly variable sulcus (the cuneal) but added an optional region on the lateral surface that is included in the LONI protocol. This region lies between two relatively robust sulci (the intraparietal and the lateral occipital) and therefore might be worth including. However, the division does not reflect cytoarchitectonic boundaries and could therefore be considered unnecessary.

Treatment of the insula. Some protocols treat the insula as a separate (5th) cerebral lobe, others include it with frontal or with temporal lobes. However, when treated separately, the circular sulcus is the consistent boundary between both the frontal and the temporal lobes. → Recommendation: Include as a uniquely labeled region.

I have included anterior and posterior insula ROIs that are divided by the central sulcus of the insula.

Arbitrary subregions. Some protocols (e.g. Iowa, MGH) further parcellate various gyri along their length using arbitrary boundaries. This is typically based on landmarks like the most anterior extent of a sulcus that would already have been identified. → Recommendation: Duplicating this may be fairly trivial, but isn't necessary for current purposes.

I suggested an optional subdivision of the cingulate gyrus that could easily be designated as arbitrary. Otherwise, I have tried to avoid this.

Other optional ROIs:

Supplementary motor cortex. Two protocols (MGH-CMA, IOWA) identify a region within the medial portion of the superior frontal gyrus that is labeled as supplementary motor area (IOWA, Crespo-Faccaro, 2000) or juxtapositional lobule (MGH-CMA, Caviness et al. 1996), an equivalent region. Anterior boundaries for these regions are arbitrary but easily identified. IOWA uses the posterior limit of the genu of the corpus callosum, MGH uses the decussation of the anterior commissure. A variation of the two definition is described here as an optional region.

Medial segments of the precentral and postcentral gyrus. The precentral and postcentral gyrus ROIs continue onto the medial surface ending at the cingulate sulcus. Anterior-posterior boundaries are formed by planes given by the medial limits of the relevant sulci on the lateral surface (i.e., precentral sulcus, central sulcus, postcentral sulcus). Desikan et al. (2006) designate a paracentral lobule region that encompasses the combined medial portions of the precentral and postcentral gyri. The region includes medial cortex dorsal to the cingulate sulcus extending from the medial limit of the precentral sulcus to the marginal ramus of the cingulate sulcus. The medial-lateral boundary of this region, the superior margin of the interhemispheric sulcus, is easily identified and robust. However, the region ignores structural (frontal and parietal lobe), cytoarchitectonic (area 4 and area 3) and functional (motor and somatosensory representations) that are commonly associated with the central sulcus. The central sulcus is a robust landmark that typically extends to the medial surface. I have therefore suggested designating individual medial segments of the precentral and postcentral gyrus, divided by the medial limit of the central sulcus, that respects the common divisions given above.

Division of the superior frontal gyrus into medial and lateral segments. Division of the large superior frontal gyrus ROI is based on the superior margin of the interhemispheric margin, an easily identified landmark. However, it ignores cytoarchitectonic boundaries.

Subdivision of the inferior frontal gyrus. The inferior frontal gyrus consists of three distinct cytoarchitectonic regions: orbital (BA 44), triangular (BA 45), and opercular (BA 47). These subdivisions are of functional interest and the boundaries between them are often approximated by the anterior ascending and anterior horizontal rami of the lateral sulcus (with some controversy). However, these sulci are often difficult to identify. Definitions of these subdivisions are given below but we should weigh interest in these regions before applying them

Subdivision of the supratemporal plane. A division of the supratemporal plane into planum temporale, transverse temporal gyrus, and planum polare ROIs, based largely upon the IOWA method, is suggested.

Subdivision of the opercular region. The dorsal bank of the lateral sulcus is labeled separately from adjacent cortex of the lateral surface and subdivided into frontal, central, and parietal ROIs based on the MGH-CMA method

Subdivisions of the cingulate gyrus (optional)

Several protocols divide the cingulate gyrus into two, three, and as many as four subregions using various landmarks. The landmarks used may be distant from the cingulate gyrus (IOWA, MGH-CMA, MGH-Desikan) and relatively unreliable (MGH-CMA). I believe it is useful to offer some subdivision of the cingulate gyrus, perhaps based upon callosal landmarks, which are relatively easy to identify but require orientation to a standard reference frame. A simple subdivision might be:

Anterior (or Genu) Cingulate Gyrus: cingulate gyrus anterior to the posterior limit of the genu of the corpus callosum

Middle Cingulate Gyrus: cingulate gyrus posterior to the posterior limit of the genu of the corpus callosum and the anterior limit of the splenium

Posterior (or Splenial) Cingulate Gyrus: cingulate gyrus posterior to the anterior limit of the splenium.

An alternative division that respects a common frontal and parietal lobe division (intersection of the central sulcus and the interhemispheric margin):

Anterior Cingulate Gyrus: cingulate gyrus anterior to the medial limit of the central sulcus.

Posterior Cingulate Gyrus: cingulate gyrus anterior to the medial limit of the central sulcus.

If the anterior cingulate given by this method is further subdivided at the posterior limit of the genu of the corpus callosum, the resulting cingulate subdivision are consistent with the IOWA method.

Gyrus Rectus and Subcallosal Cortex. These regions are included in several protocols but definitions vary and often rely upon axially oriented planes or the infero-medial hemispheric margin. I suggest a definition that relies on the inferior rostral sulcus, a landmark that may prove too variable.

Occipital Fusiform Gyrus. A subdivision of the fusiform gyrus based on the temporal lobe/occipital lobe boundary on inferior surface. The area between the occipitotemporal and collateral sulci anterior to the antero-medial limit of the ventral bank of the parietooccipital sulcus is labeled as Fusiform Gyrus. The area between these sulci that lies posterior to the antero-medial limit of the parietooccipital sulcus is labeled Occipital Fusiform Gyrus.

References

- Bowden, D. & Dubach, M. (2003). NeuroNames 20002. *Neuroinformatics*, 1(1), 43-59.
- Buchanan, R., Francis, A., Arango, C., Miller, K., Lefkowitz, D., McMahon, R., Barta, P. & Pearlson, G. (2004). Morphometric assessment of the heteromodal association cortex in schizophrenia. *American Journal of Psychiatry*, 161, 322-331.
- Carper, R. & Courchesne, E. (2000). Inverse correlation between frontal lobe and cerebellum sizes in children with autism. *Brain*, 123, 836-844.
- Carper, R. & Courchesne, E. (2005). Localized enlargement of the frontal cortex in early autism. *Biological Psychiatry*, 57(2), 126-133.
- Carper, R., Moses, P. Tigue, Z. D. & Courchesne, E. (2002). Cerebral lobes in autism: early hyperplasia and abnormal age effects. *Neuroimage*, 16(4), 1038-1051.
- Caviness, V. S., Meyer, J., Makris, N. & Kennedy, D. (1996). MRI-based topographic parcellation of human neocortex: an anatomically specified method with estimate of reliability. *Journal of Cognitive Neuroscience*, 8(6), 566-587.
- Crespo-Facorro, B., Kim, J., Andreasen, N. C., Spinks, R., O'Leary, D. S., Bockholt, H. J., Harris, G. & Magnotta, V. A. (2000). Cerebral cortex: a topographic segmentation method using magnetic resonance imaging. *Psychiatry Research*, 100(2), 97-126.
- Desikan, R. S., Segonne, F., Fischl, B., Quinn, B. T., Dickerson, B. C., Blacker, D., Buckner, R. L., Dale, A. M., Maguire, R. P., Hyman, B. T., Albert, M. S. & Killiany, R. J. (2006). An automated labeling system for subdividing the human cerebral cortex on MRI scans into gyral based regions of interest. *Neuroimage*, 31(3), 968-980.
- Duvernoy, H. M. (1999). *The human brain: Surface, blood supply, and three dimensional anatomy*. New York: Springer-Verlag Wien.
- Kim, J. J., Crespo-Facorro, B., Andreasen, N. C., O'Leary, D. S., Zhang, B., Harris, G. & Magnotta, V. A. (2000). An MRI-based parcellation method for the temporal lobe. *Neuroimage*, 11(4), 271-88.
- Mai, J., Paxinos, G. & Voss, T. (2008). *Atlas of the human brain*. New York: Elsevier.
- McCarley, R. & Shenton, M. (2008). *Structural MRI laboratory manual: MR image acquisition and image processing tools and neuroanatomical regions of interest*, Harvard University.
- Ono, M., Kubik, S. & Abernathy, C. D. (1990). *Atlas of the cerebral sulci*. Stuttgart: Georg Thieme Verlag.
- Shattuck, D., Mirza, M., Adisetiyo, V. H., C, Salamon, G., Narr, K., Poldrack, R., Bilder, R. & Toga, A. (2008). Construction of a 3D probabilistic atlas of human cortical structures. *Neuroimage*, 39(3), 1064-1080.
- Tourville, J. A. & Guenther, F. H. (2003). A cortical parcellation scheme for speech studies. *Boston University Technical Report CAS/CNS-03-022*. Boston, MA, Boston University.
- Zhou, S., Suzuki, M., Takahashi, T., Hagino, H., Kawasaki, Y., Matsui, M. S., H & Kurachi, M. (2007). Parietal lobe volume deficits in schizophrenia spectrum disorders. *Schizophr Research*, 89(1-3), 35-48.